

Article

Liver Histological Effects Induced by Frying Fodder with Olive Oil, Bay Leaves and Ginger Roots on Healthy Mice

Rahman J. Younis¹, Abdullah M. Ajil², Irfan W. Mahmood³

1,3. Department of Science, College of Basic Education/Shirqat, Tikrit University, 34005, Salah Al Deen, Iraq

2. Department of Dairy Science and Technology, College of Food Sciences Al-Shirqat, 34005, Salah Al Deen, Tikrit University

*Correspondence: abdulrahman.j.younis@tu.edu.iq

Abstract: Humans have studied the importance of plants and their oils, classifying them as beneficial or harmful, and have used healthy ones to treat diseases, as most published research discusses the benefits of oils when they are fresh. Therefore, the current study aimed to evaluate the histological effects of certain oils when fried and to investigate the potential protective effects of medicinal plants possessing detoxifying properties. These oils are widely used in cooking, as they are generally considered healthy and harmless to the body. Male and female mice were divided into four groups: a control group, food that was fried in olive oil, Boil the food in olive oil with ginger and bay leaves separately. The injection was administered intravenously in a concentrated form, resulting in the deterioration of many liver cells, localized necrosis in others, nuclear pyknosis, and dilatation of blood sinusoids were seen in the group fed meals fried in olive oil, and a size and number increasing of liver macrophages. Severe hyperemia in the portal vein, fibrin deposition on one side of its lumen, and Additionally, there was a substantial infiltration of inflammatory cells. On the other hand, the group that was given food that was fried in olive oil with bay leaves and the group that was fed food that was fried in olive oil with ginger roots both had almost normal histological structure.

Keywords: Ginger Roots, Bay Leaves, Olive Oil, Liver

Citation: Younis, A-R. J., Ajil, A. M., Mahmood, I. W. Liver Histological Effects Induced by Frying Fodder with Olive Oil, Bay Leaves and Ginger Roots on Healthy Mice. Central Asian Journal of Theoretical and Applied Science 2026, 7(2), 114-120.

Received: 18th Feb 2025

Revised: 06th Mar 2025

Accepted: 20th Mar 2026

Published: 08th Apr 2026



Copyright: © 2026 by the authors. Submitted for open access publication under the terms and conditions of the Creative Commons Attribution (CC BY) license (<https://creativecommons.org/licenses/by/4.0/>)

1. Introduction

Cooking is one of the fundamental steps in food preparation in the modern era. Primary oxidized triacylglycerols are produced when oils and fats are thermally fried [1]. These compounds are often absorbed by food and enter the human body, where they form components of the blood [2]. The liver is one of the areas of the body that they could get to. Even when cooking with olive oil, one of the primary problems linked to oxidized lipids in the liver is non-alcoholic fatty liver disease [3]. Oxidized lipids have been reported to cause hepatitis and chronic adenoma, thereby promoting cancer in mice [4]. Because olive oil has a lower smoke point (≈ 205 °C) than other oils including peanut oil (≈ 225 °C), sunflower oil (≈ 255 °C), soybean oil (≈ 242 °C), and palm oil (≈ 227 °C), several research have investigated the potential risks of using olive oil for frying [5]. It is believed that more fat oxidation is indicated by a lower smoke point. In contrast to previous beliefs, research has recently shown that smoke point does not predict the performance and stability of oils. The stability/quality of EVOO is also improved by its high content of monounsaturated fatty acids compared to polyunsaturated fatty acids, and by the presence of antioxidants which help prevent degradation of EVOO during cooking processes [6].

Some studies suggest that the heating time should be kept to a minimum in order to maintain the physiologically active components of virgin olive oil. However, because of its balanced major and minor component makeup, olive oil often performs on par with or better than other refined vegetable oils when heated for extended periods of time. However, using lower grades of olive oil with periodic renewal may be more cost-effective because the majority of its beneficial components, including phenolic compounds, are progressively lost over continuous heating. Future research on the heat breakdown processes of olive oil constituents and their effects on human health will be especially beneficial [7].

Because pure olive oil is high in monounsaturated fatty acids and low in polyunsaturated fatty acids, as well as because its antioxidant contents protect against heat degradation during cooking, several studies have claimed that it is one of the finest oils for frying [8]. Bay leaves and ginger may be added to oil to lessen oxidation. Several studies have shown how important it is to use these ingredients while cooking to minimize oxidation and eliminate unwanted aromas [9, 10].

2. Materials and Methods

2.1 The Materials used in the experiment

- a. Oil Virgin olive
- b. Roots Ginger
- c. Bay leaves

2.2 Experiment design

Twenty mice were randomly divided into four groups, with five animals in each group, weighing between 120 and 124 grams and aged between 12 and 15 weeks, as shown below.

- a. The control group was provided with a standard diet made of yellow maize, soybean meal (44% soy), corn gluten (62% corn), barley, vitamins and minerals, limestone, dicalcium phosphate, salt, L-lysine monohydrochloride, and methionine for thirty days along with drinking water (98.5%). The chosen standard meal was fried in olive oil at its smoke point for ten minutes, filtered to remove excess oil, and then mixed 1:1 with the unfried diet because the mice's mortality was caused by the fried diet alone.
- b. The specified standard diet was fried for ten minutes at the smoke point in olive oil supplemented with bay leaves, filtered to remove extra oil, and combined 1:1 with the unfried diet.
- c. Fresh and fried ginger roots were added to the usual diet and cooked in olive oil for ten minutes at the smoke point. The surplus oil was then filtered out and combined 1:1 with the unfried diet.

2.3 Preparing histological sections

The following procedures were used to make tissue sections in accordance with the Luna technique [11]: Fixing, coloring, embedding, penetrating, washing, drying, cleaning, cutting, assembling, and trimming.

3. Results

3.1 Control Group

Microscopic examination revealed the normal structure of the hepatic parenchyma, which is composed of hepatic cords or plates formed by polygonal hepatocytes, each containing one or two spherical or oval nuclei with dispersed chromatin. Hepatocytes were arranged radially around the central vein and were separated by blood spaces representing hepatic sinusoids containing phagocytic Kupffer cells with dark, spherical nuclei, as shown in Figures 1 and 2.

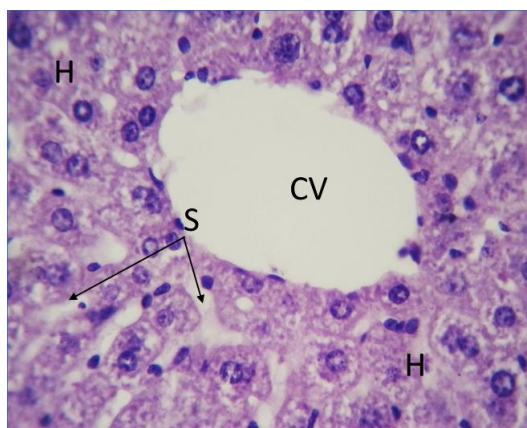


Figure 1. Image of the liver of a mouse from the control group, in which the hepatocytes (H) are arranged radially around the central vein (CV), separated by sinusoids (S). (H&E, X400).

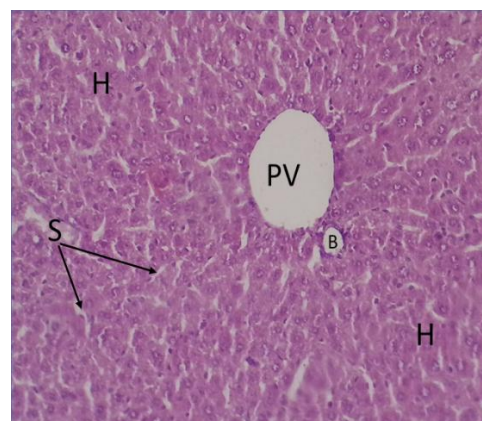


Figure 2. Image of the liver of a mouse from the control group, in which the hepatocytes (H) are arranged radially around the portal vein (PV), as well as the normal shape of the bile duct (B) and sinusoids (S). (H&E, X100).

3.2 Fried Olive Oil Group

The results showed the central venous congestion, degeneration in several hepatocytes, focal necrosis in others, nuclear pyknosis, dilation of blood sinusoids, and an increase in the number and size of Kupffer cells. Severe hyperemia of the portal vein, fibrin deposition on one side of its lumen, and dense infiltration of inflammatory cells were also observed, as shown in Figures 3 and 4.

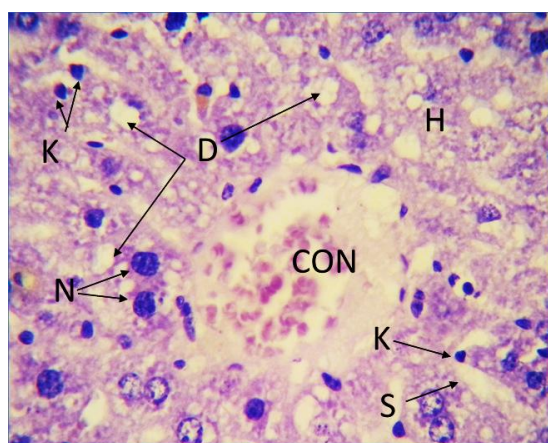


Figure 3. A microscope image of a mouse's liver from the group whose meal was prepared in olive oil, showing congestion of the central vein (CON), degeneration in a number of hepatocytes (H), focal necrosis in a number of others (D), nuclear pyknosis (N), is observed. Expansion of the number of sinusoids (S), increase in the number and size of Kupffer cells (K). (H&E, X400).

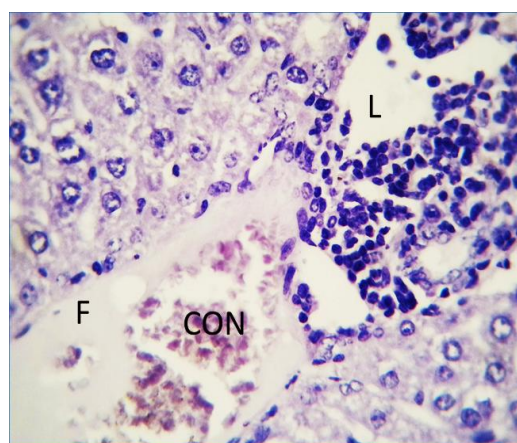


Figure 4. A microscopic image of a mouse's liver from the group whose meal was fried in olive oil, in which severe hyperemia is observed in the portal vein (CON), fibrin deposition on one side of its lumen (F), as well as dense infiltration of inflammatory cells in it (L). (H&E, X400).

3.3 Fried Olive Oil with Bay Leaves Group.

The results shown in Figures 5 and 6 demonstrated an almost normal appearance of the portal vein and the two branches of the bile duct in some sections, and a completely normal appearance in other. Mild degenerative changes were observed in a few cells. Overall, a significant improvement was noted compared to the fried olive oil-only group,

which exhibited severe portal vein hyperemia, fibrin deposition on one side of its lumen, and dense inflammatory cells infiltration.

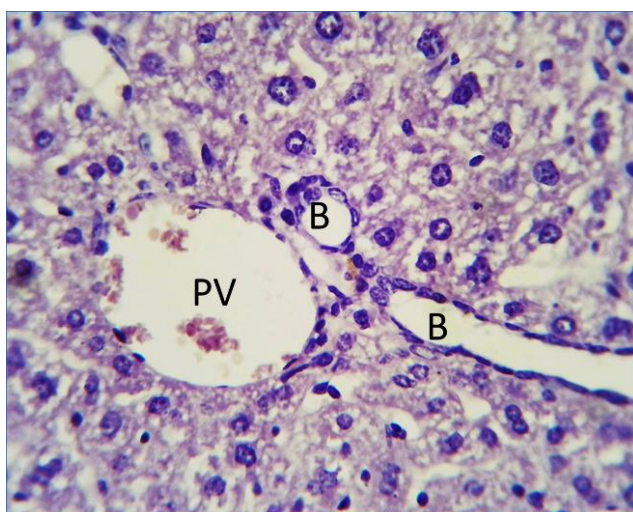


Figure 5. A microscopic picture of a mouse's liver from the group that used bay leaves and olive oil to fry its food, in which the almost normal appearance of the portal vein (PV) and the two branches of the bile ductules (B) are noted. (H&E, X400).

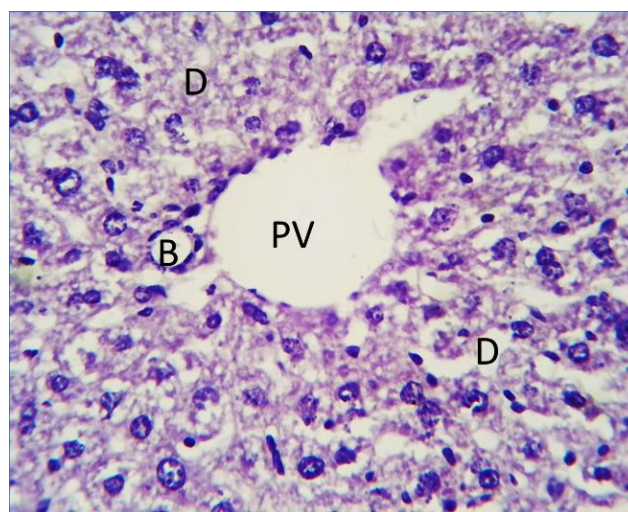


Figure 6. A microscopic picture of the liver of a mouse from the group that fried their fodder in olive oil with bay leaves, in which a normal branch of the hepatic portal vein (PV) and a branch of the bile duct (B) are observed, surrounded by many degenerative cells (D). (H&E, X400).

3.4 Fried Olive Oil with Ginger Roots Group.

The results showed a normal appearance of the portal vein and its two branches of the bile duct. Hepatocytes were radially arranged around the central vein, which also appeared normal, as shown in Figures 7 and 8. A clear improvement was observed compared to the fried olive oil – only group. In contrast, the fried olive oil – only group exhibited acute hyperemia in the portal and central veins, fibrin deposition on one side of the portal vein lumen and dense inflammatory cells infiltration in its walls.

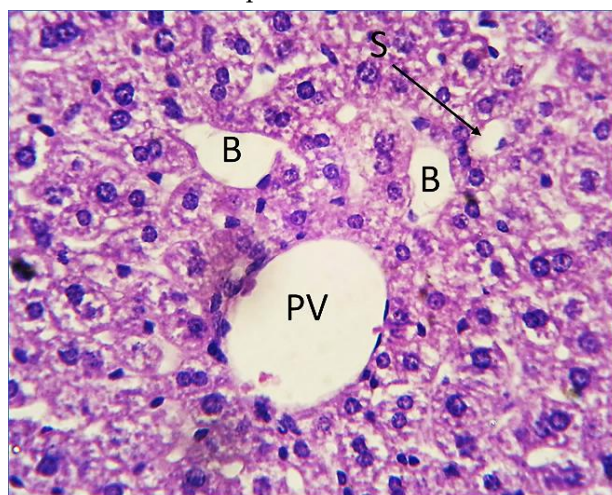


Figure 7. We have a histology of the liver of the mouse in the group that fried its fodder with the ginger roots and olive oil; it is seen that there is a normal appearance of the portal vein (A), the two ducts of the bile (B), and an expansion of a number of blood sinuses (S). (H&E, X400).

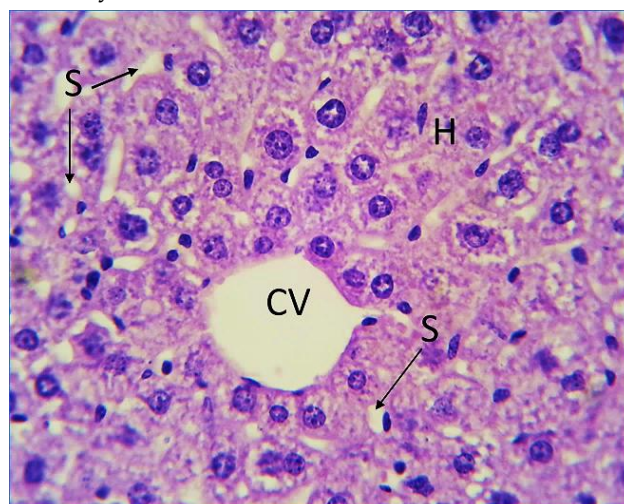


Figure 8. A microscopic image of a mouse liver taken from The group who deep fried their food with olive oil and ginger roots. The hepatocytes (H) are organized in a radial configuration around the central vein (CV) with sinusoidal spaces (S) in between them. (H&E; X400).

4. Discussion

Histological examination of the liver of the mice fed fodder fried in olive oil revealed the presence of histopathological lesions. These lesions may be attributed to the livers central role in metabolism, detoxification, storage, and secretion of essential substances and their metabolites, making it particularly vulnerable to damage. Central vein congestion and cellular degeneration were observed in several hepatocytes. These changes may be associated with the frying process of olive oil, as high temperatures can lead to oxidative stress and the formation of toxic compounds that contribute to hepatic injury. Significant chemical changes occur in oils, specifically through oxidation and polymerization, which may include oxidative stress and consequently lead to long-term tissue damage. This was observed in the present experiment, which lasted 30 days [12, 13]. Although olive oil exhibited greater stability than many edible oils, thermal processing can alter certain EVOO components, leading to the formation of peroxides, polar compounds, and aldehydes that may contribute to long-term tissue injury. These findings are consistent with previously reported results [14].

The group fed olive oil-fried feed supplemented with bay leaves showed a near-normal appearance of the portal vein and bile duct branches in some sections, and a completely normal appearance in others. This improvement is attributed to the bioactive properties of bay leaves, which are rich in antioxidants, minerals, and phenolic compounds [15,16].

Supplementation with bay leaves resulted in significant improvement compared to the olive oil –only group. These findings support the protective effects of bay leaves and consistent with the findings reported by Singletary (2021) [17].

The group fed fodder fried in olive oil supplemented with ginger roots showed a normal appearance of the portal vein and the two bile duct branches, as well as preserved hepatic structure. The characteristic radial arrangement of hepatocytes around the central vein was preserved and appeared normal. Compared to the group fed fodder fried in olive oil alone, which exhibited severe acute hyperemia in the portal and central vein, in addition to fibrin deposition on one side of the portal vein lumen and dense inflammatory cells infiltration in its walls. The results were superior to those of the bay leaf – treated group, possibly due to the potent antioxidants properties of ginger root. Ginger contains antioxidants that reduce lipid oxidation and its essential oils and oleoresins exhibit antioxidant activity. Studies have shown that 6-dehydroshogaol, 6-shogaol and 1 - dehydro-6-gingerdione present in ginger inhibits nitric oxide synthesis in activated macrophages [18]. 6-shogaol showed significant antioxidant action. Furthermore, ginger's phenolic components decreased the inhibition of the xanthine oxidation system and prevented lipid peroxidation in the FeCl₃-ascorbate system, respectively. The activity of xanthine oxidase is caused by these mechanisms. Superoxide anions and other reactive oxygen species (ROS) are produced by these systems [19,20]. According to some research, 6-shogaol-rich ginger extract activates nuclear factor erythroid 2-related factor 2 (Nrf2) signaling pathways to improve antioxidant defense mechanisms [21, 22, 23].

5. Conclusion

The use of fried olive oil may cause long – term liver tissue damage, whereas the addition of bay leaves and ginger during cooking may reduce these harmful effects and improve liver health. The degradation of olive oil under frying conditions is a complex chemical process due to the formation of numerous compounds generated through interactions and reactions occurring under thermal stress, which may have potential health implications. Therefore, incorporating natural antioxidant – rich additives such as bay leaves and ginger root during frying may represent a particle strategy to minimized oxidative damage associated with thermally processed oils.

6. Acknowledgements

The researchers thank the Presidency of Tikrit University /Republic of Iraq for the facilities provided to all researchers by providing laboratory equipment and devices to complete their scientific research.

REFERENCES

- [1] A. Zeb, "Chemistry and liquid chromatography methods for the analyses of primary oxidation products of triacylglycerols," *Free Radical Research*, vol. 49, no. 5, pp. 549–564, 2015, doi: 10.3109/10715762.2015.1022540.
- [2] I. Staprans, D. A. Hardman, X. M. Pan, and K. R. Feingold, "Effect of oxidized lipids in the diet on oxidized lipid levels in postprandial serum chylomicrons of diabetic patients," *Diabetes Care*, vol. 22, no. 2, pp. 300–306, 1999, doi: 10.2337/diacare.22.2.300.
- [3] A. Tiwari, A. Shukla, and P. Kumar Samal, "Evaluation of anti-hyperlipidemic and anti-atherogenic activity of asiatic acid and its effect on lipid peroxidation in hyperlipidemic rats," *Journal of Biochemical and Molecular Toxicology*, vol. 39, no. 5, p. e70255, 2025, doi: 10.1002/jbt.70255.
- [4] A. Zeb and A. A. Khan, "Improvement of serum biochemical parameters and hematological indices through α -tocopherol administration in dietary oxidized olive oil induced toxicity in rats," *Frontiers in Nutrition*, vol. 5, p. 137, 2019, doi: 10.3389/fnut.2018.00137.
- [5] P. K. Nayak, U. M. A. Dash, K. Rayaguru, and K. R. Krishnan, "Physio-chemical changes during repeated frying of cooked oil: A review," *Journal of Food Biochemistry*, vol. 40, no. 3, pp. 371–390, 2016, doi: 10.1111/jfbc.12215.
- [6] C. S. Santos, L. Molina-Garcia, S. C. Cunha, and S. Casal, "Fried potatoes: Impact of prolonged frying in monounsaturated oils," *Food Chemistry*, vol. 243, pp. 192–201, 2018, doi: 10.1016/j.foodchem.2017.09.117.
- [7] R. Ambra, S. Lucchetti, and G. Pastore, "A review of the effects of olive oil-cooking on phenolic compounds," *Molecules*, vol. 27, no. 3, p. 661, 2022, doi: 10.3390/molecules27030661.
- [8] C. Jimenez-Lopez *et al.*, "Bioactive compounds and quality of extra virgin olive oil," *Foods*, vol. 9, no. 8, p. 1014, 2020, doi: 10.3390/foods9081014.
- [9] S. Batool, R. A. Khera, M. A. Hanif, and M. A. Ayub, "Bay leaf," in *Medicinal Plants of South Asia*, pp. 63–74, 2020, doi: 10.1016/B978-0-08-102659-5.00005-7.
- [10] P. Ballester, B. Cerdá, R. Arcusa, J. Marhuenda, K. Yamedjeu, and P. Zafrilla, "Effect of ginger on inflammatory diseases," *Molecules*, vol. 27, no. 21, p. 7223, 2022, doi: 10.3390/molecules27217223.
- [11] L. G. Luna, *Manual of Histologic Staining Methods of the Armed Forces Institute of Pathology*. New York: McGraw-Hill, 1968.
- [12] S. Casal, R. Malheiro, A. Sendas, B. P. Oliveira, and J. A. Pereira, "Olive oil stability under deep-frying conditions," *Food and Chemical Toxicology*, vol. 48, no. 10, pp. 2972–2979, 2010, doi: 10.1016/j.fct.2010.07.036.
- [13] C. S. Santos, R. Cruz, S. C. Cunha, and S. Casal, "Effect of cooking on olive oil quality attributes," *Food Research International*, vol. 54, no. 2, pp. 2016–2024, 2013, doi: 10.1016/j.foodres.2013.04.014.
- [14] D. Zhao *et al.*, "Oxidative stability of phytosterols in camellia seed oil during heating: The impact of different antioxidants," *Foods*, vol. 14, no. 13, p. 2297, 2025, doi: 10.3390/foods14132297.
- [15] M. M. Bakr, H. M. Taher, F. K. Hussein, and A. H. Mohamed, "Study the effective role of metronidazole nanoemulsion for the treatment of skin lesions in mice induced by *Entamoeba histolytica*," *South Asian Research Journal of Biology and Applied Biosciences*, vol. 6, no. 1, pp. 1–7, 2024, doi: 10.36346/sarjbab.2024.v06i01.001.
- [16] A. Sharma, J. Singh, and S. Kumar, "Bay leaves," in *Handbook of Herbs and Spices*, pp. 73–85, 2012, doi: 10.1533/9780857095671.73.
- [17] K. Singletary, "Bay leaf: Potential health benefits," *Nutrition Today*, vol. 56, no. 4, pp. 202–208, 2021, doi: 10.1097/NT.0000000000000493.
- [18] C. Nutakor, J. A. Essiedu, P. Adadi, and O. N. Kanwugu, "Ginger beer: An overview of health benefits and recent developments," *Fermentation*, vol. 6, no. 4, p. 102, 2020, doi: 10.3390/fermentation6040102.

-
- [19] M. Zhang *et al.*, "Ginger (*Zingiber officinale* Rosc.) and its bioactive components are potential resources for health beneficial agents," *Phytotherapy Research*, vol. 35, no. 2, pp. 711–742, 2021, doi: 10.1002/ptr.6858.
- [20] R. H. Ali, F. K. Hussein, D. M. Nasar, and A. Abd Al Salam Salem, "The relevance of mitochondrial DNA mutation in human diseases and forensic sciences," *Al-Nahrain Journal of Science*, vol. 28, no. 1, pp. 96–106, 2025, doi: 10.22401/ANJS.28.1.11.
- [21] I. Bischoff-Kont and R. Fürst, "Benefits of ginger and its constituent 6-shogaol in inhibiting inflammatory processes," *Pharmaceuticals*, vol. 14, no. 6, p. 571, 2021, doi: 10.3390/ph14060571.
- [22] S. R. Hasan, F. M. Junaid, B. M. Mahdi, and F. K. Hussein, "Therapeutic applications of medicinal plants for the treatment of human intestinal diarrhea: Review article," *South Asian Journal of Life Sciences*, vol. 13, pp. 20–24, 2025, doi: 10.17582/journal.sajls/2025/13.20.24.
- [23] R. H. Ma *et al.*, "A recent update on the multifaceted health benefits associated with ginger and its bioactive components," *Food & Function*, vol. 12, no. 2, pp. 519–542, 2021, doi: 10.1039/D0FO02834G.